

Innovations

The Crucial Role of Pathologists: A Comprehensive Literature Review

¹Dr. V.S. Apoorva, ^{*2} Dr. Beeula. A, ³Saranya M

¹Intern, Adhiparasakthi Dental College and Hospital, Melmaruvathur 603 319

^{*2} Senior lecturer, Adhiparasakthi Dental College and Hospital, Melmaruvathur 603 319

³ Intern, Adhiparasakthi Dental College and Hospital, Melmaruvathur 603 319

*Corresponding author: **Dr. Beeula. A**

Abstract

In the field of dentistry, the presence of an oral pathologist is important, as they play a key role in diagnosing, managing, and preventing diverse oral diseases. Specializing in the examination of the characteristics and development of oral conditions, oral pathologists make substantial contributions to the holistic healthcare of individuals. The timely and correct detection of oral diseases, such as infections, immune-mediated disorders, and malignancies, is one of the main duties of an oral pathologist. Oral pathologists use their knowledge to recognize and categorize conditions affecting the oral tissues by carefully reviewing patient histories, clinical observations, and laboratory tests. This diagnostic understanding is essential for developing suitable treatment strategies and assisting medical professionals in delivering focused, efficient care. This review emphasizes the prominence of the role of an oral pathologist in the realm of dentistry and their necessary guidance in the diagnosis and management of histopathological studies.

Key words: Biopsy, Histopathology, Diagnosis, Management

Introduction:

Pathology, frequently known as the "study of diseases," holds a crucial position in contemporary medicine. Central to this field is the pathologist, a healthcare expert tasked with examining the characteristics and origins of illnesses. Pathology focuses on the examination of tissue at both macroscopic and microscopic levels, aligning it with the patient's clinical and radiographic background, ultimately aiding in the formulation of a precise diagnosis. (1, 2) The dental field is increasingly emphasizing disease detection and advancing diagnostic methods. In oncology, biopsies are crucial for diagnosing malignancies, determining tumor histology, and analyzing metastasis for staging.(3,4) Oral pathologists, having acquired expertise through substantial experience and clinical knowledge, recognize and diagnose evident signs of diseases but also comprehend and analyze their microscopic characteristics. The increasing relevance of molecular-based technologies, immunology, and genetics has elevated the importance of this specialized field. (5, 6, 7) With specialized training, oral pathologists can establish more precise correlations between pathological and clinical observations with a broader focus on surgical pathology empowering them to offer more accurate and dependable diagnoses. (8, 9) This review examines the diverse responsibilities of pathologists, investigating their involvement in diagnostics, research, and patient care.

Biopsy:

Biopsy is the removal of the tissue from the living organism for the purpose of microscopic examination and diagnosis (Shafer et al., 1983). The WHO in 1966 defined "biopsy as the examination of tissue removed from a lesion and by extension the term is also used to convey the removal of the tissue".

Types of biopsy

Various biopsy techniques are available, each tailored to specific situations and types of tissues. The following are commonly utilized biopsy techniques: (Fig 1)

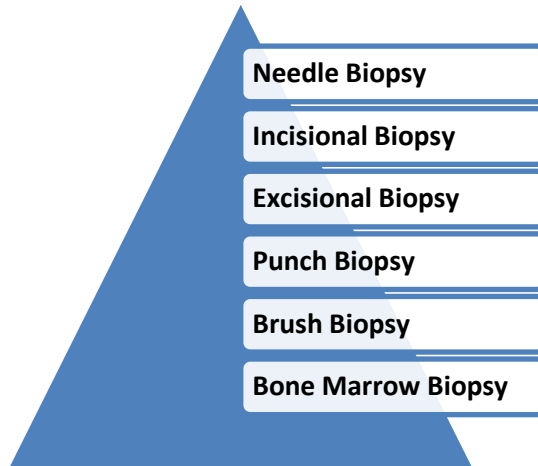


Fig 1: Types of Biopsy

Needle Biopsy:

- Fine Needle Aspiration Cytology (FNAC): Involves extracting a small cell sample from a suspicious lump or mass using a thin, hollow needle. Performing Fine Needle Aspiration Cytology (FNAC) without the aid of radiological guidance is a swift, efficient, and cost-effective method for assessing superficial masses that are easily visible. Eg: breast and thyroid tissues. (10, 11, 12)
- Core Needle Biopsy: The novel cutting needle biopsy (CNB) approach represents a quicker, safer, and less invasive method. This procedure can be conducted using local anesthesia and yields a tissue sample suitable for a dependable histological diagnosis. (13, 14, 15)

Incisional Biopsy:

- Involves the partial removal of abnormal tissue for examination. In the case of porokeratosis, the incision stretches from the center of the circular patch, through the elevated border, and into the surrounding normal skin. This is done to observe all three zones effectively. (16)

Excisional Biopsy:

- Involves the complete removal of abnormal tissue or the entire lesion, often chosen when safe excision of the entire mass is possible. It is commonly used for small tumors or cysts.

Punch Biopsy:

- This method is the most commonly employed approach for skin biopsy, serving dual purposes for both diagnosis and treatment. It is applicable for various conditions such as punch excision of small pyogenic granuloma, verruca, and tattoo removal. The technique is suitable for any solid lesion or small vesicle that fits within the punch.(16) Utilizes a circular tool to extract a small, cylindrical tissue piece from the skin or mucous membranes, frequently used for dermatological conditions.

Brush Biopsy:

- Involves using a brush-like instrument to collect cells from the surface of a lesion or organ, often employed for areas with a large surface area, such as the cervix during a Pap smear. This approach is commonly employed as the primary screening technique for detecting oral cancer or precancerous lesions in the oral cavity. (17) Samples from oral brushing are centrifuged onto slides and treated with the Feulgen-thionin reaction for staining.

Bone Marrow Biopsy:

- Used to examine bone marrow cells, typically from the hip bone. A needle is inserted into the bone to extract a small core of bone marrow, which is then analyzed for various blood disorders or cancers. The procedure is often carried out using either palpation-guided or computed tomography-guided (CT-guided) techniques. Both methods demonstrate a high level of precision and a low incidence of complications. Eg: leukemia and other bone malignancies. (18)

The choice of biopsy technique depends on the suspected condition, the location of the abnormal tissue, and the size of the lesion. After collection, the samples are sent to a pathology laboratory for analysis, where specialists provide a definitive diagnosis. It's crucial to note that the selection of the biopsy technique is determined by the specific clinical scenario and the expertise of the medical team.

Consideration during biopsy procedure:

- Primarily and significantly, surgeons need to take necessary measures to prevent the introduction of foreign material, particularly tissue from another patient, in order to avoid contamination.
- The risk exists in various settings such as the operating room, clinic, or any stage of the pathology procedure when examining the tissue. Samples taken from the mouth are typically tiny, increasing the likelihood of creating artifacts.
- Artifacts result from various procedures, including Injection, forceps usage, fulguration, laser application, and suction. A prevalent problem with injections arises when an excessive amount of anesthetic solution is delivered too quickly, leading to the separation of connective tissue bundles. (19, 20)
- To prevent this, it is advised to refrain from injecting anesthetic agents directly into the lesion. In the context of examining and sampling tissues, the evaluation of surgical margins is a vital step and it is believed that if a positive margin is not addressed, it could lead to local recurrence. (1)
- The usual procedure for this assessment includes the application of India ink or a similar pigment on the margins before cutting the specimen. This can be performed on either the fresh specimen or, after fixation, by delicately wiping the margins with gauze and meticulously covering the entire surgical surface with India ink using a cotton swab stick. (21)

Considerations during Fixation and Transportation:

- It varies depending on the specific chemical substances present in tissues and is crucial to promptly initiate fixation with a suitable and effective fixative following tissue removal.
- The amount of fixative used should be 15–20 times more than the overall size of the tissue to ensure complete coverage from all angles.
- Overnight fixation is acceptable to support primary fixation of large samples where as for small samples 12 hours are recommended.
- If the specimens settle at the bottom of the container, placing gauze between the container bottom and the specimen is recommended. (22, 23)
- While fixation is employed to avoid the development of different artifacts, it can paradoxically contribute to the formation of various artifacts. Research indicates that formalin-fixed paraffin-embedded specimens undergo 33% shrinkage. Moreover, extended exposure to formalin during fixation has been observed to result in subsequent shrinkage. It is noteworthy to highlight that normal saline solution provides minimal fixation. (22, 23, 24)
- Problems with timely and proper fixation can impact the staining of cells, leading to observable changes such as cell shrinkage, cytoplasmic clumping, indistinct nuclear chromatin, and occasionally, the absence of nucleoli. These alterations have significant implications for the management of oral biopsies, particularly those associated with dysplasia and carcinomas. (20)
- In case of standard histo-pathological procedures, it is recommended to perform fixation at room temperature. In cases where urgent biopsy specimens require quick fixation, heated formalin at 60°C has been employed. Furthermore, tissue affected by tuberculosis can be fixed using formaldehyde at 100°C. (22)
- Void structures like cystic cavities are addressed by either immediate opening or simultaneous external and internal fixation. The empty cavity is filled with formalin through methods such as syringe or catheter injection, or by placing formalin-soaked gauze or cotton within. When dealing with cystic lesions, formalin is introduced after draining the initial fluid. Larger cavities in multilocular cysts may require separate injections. (21)
- In addition to standard histopathology, various techniques such as electron microscopy, immunohistochemistry, fluorescent microscopy, enzyme-histochemistry and exfoliative cytology are becoming integral to routine diagnosis. Therefore, it is essential to precisely determine the specific type of fixative required for these diverse techniques.

Critical information that needs to be conveyed to pathologists:

Each tissue should be accompanied by an accurate requisition form, assigning it a unique identification number and including clinical details such as location, size, shape, and dimensions. It is essential to note the dimensions based on clinical observation and post-excision, as tissues may experience changes like swelling or shrinking in the fixative. Additionally, for certain specimens like cysts; there is a risk of content loss during transportation. It's crucial to emphasize the need for a prompt report since histopathology reports can be delivered within a short timeframe, ranging from ten minutes (using a cryostat) to one day. However, certain situations, such as the need for special tests or the inclusion of bony tissue in the specimen, may extend the processing time to a few weeks. In numerous surgical procedures, surgeons are often aware of the microscopic diagnosis of the lesion. However, their focus shifts to obtaining details such as the extent of the lesion, invasion of adjacent structures, presence of tumors at surgical margins, vascular involvement, and lymph node metastasis. It is essential to have the guidance of an oral pathologist when undertaking such endeavors. (1, 22, 25)

Conclusion:

The oral pathologist plays a critical role in research and education within the dental community. In conclusion, the role of an oral pathologist in dentistry is multifaceted and integral to the overall oral healthcare system. Through accurate diagnosis, research contributions, and educational efforts, oral pathologists prominently enhance the quality of patient care and additionally also contribute to the advancement of dental science. Their expertise is vital in shaping preventive measures and ensuring the early detection of oral diseases, thereby playing a crucial part in maintaining and promoting oral health.

References:

1. Jain N. *Essentials before sending biopsy specimens: A surgeon's prespective and pathologists concern. Journal of maxillofacial and oral surgery.* 2011 Dec;10(4):361-4.
2. Melo bs, arantes eb, dalla riva yg, lourenço sd, sartoretto s, resende rf, alves at. *The importance of the oral pathologist in the diagnostic process of injuries oromaxillofacials: case report. Oral Surgery, Oral Medicine, Oral Pathology and Oral Radiology.* 2022 Sep 1;134(3):e134.
3. Bernstein ML. *Biopsy technique: the pathological considerations. The Journal of the American Dental Association.* 1978 Mar 1;96(3):438-43.
4. Marshall D, LaBerge JM, Firetag B, Miller T, Kerlan RK. *The changing face of percutaneous image-guided biopsy: molecular profiling and genomic analysis in current practice. Journal of Vascular and Interventional Radiology.* 2013 Aug 1;24(8):1094-103.
5. Maqsood A, Faheem S, Mirza D, Qayum Z, Lal A, Altamash S, Ahmed N, Heboyan A. *An insight into perceptions of general pathologists about the need for oral pathology services: An observational study. SAGE Open Medicine.* 2023 Sep.
6. Saluja P, Khurana C, Dave A, Arora M, Kumar S. *Perception and willingness toward oral pathology and histology as a subject and profession among Indian dental undergraduates. Dental Research Journal.* 2020 Nov;17(6):472.
7. Chang JY, Lin TC, Wang LH, Cheng FC, Chiang CP. *Views of young dentists on choosing oral pathology specialist as their lifelong career. Journal of Dental Sciences.* 2021 Oct 1;16(4):1102-9.
8. Naz S, Hashmi AA, Khurshid A, Faridi N, Edhi MM, Kamal A, Khan M. *Diagnostic role of fine needle aspiration cytology (FNAC) in the evaluation of salivary gland swelling: an institutional experience. BMC research notes.* 2015 Dec;8:1-5.
9. Asim M, Mudassir G, Hashmi AA, Abid M, Sheikh AK, Naveed H, Habib M, Edhi MM, Khan A. *Diagnostic accuracy of fine needle aspiration biopsy in pediatric small round cell tumors. BMC research notes.* 2018 Dec;11:1-5.
10. Naz S, Hashmi AA, Faridi N, Edhi MM, Kamal A, Khan M. *Diagnostic accuracy of Bethesda system for reporting thyroid cytopathology: an institutional perspective. International archives of medicine.* 2014 Dec;7(1):1-5.
11. Wan YL, Chan SC, Chen YL, Cheung YC, Lui KW, Wong HF, Hsueh C, See LC. *Ultrasonography-guided core-needle biopsy of parotid gland masses. American journal of neuroradiology.* 2004 Oct 1;25(9):1608-12.
12. Cevik FC, Aykin N, Naz H. *Complications and efficiency of liver biopsies using the Tru-Cut biopsy Gun. The Journal of Infection in Developing Countries.* 2010;4(02):091-5.
13. Screatton NJ, Berman LH, Grant JW. *Head and neck lymphadenopathy: evaluation with US-guided cutting-needle biopsy. Radiology.* 2002 Jul;224(1):75-81.
14. Nischal U, Nischal KC, Khopkar U. *Techniques of skin biopsy and practical considerations. Journal of cutaneous and aesthetic surgery.* 2008 Jul;1(2):107.

15. Yang G, Wei L, Thong BK, Fu Y, Cheong IH, Kozlakidis Z, Li X, Wang H, Li X. A systematic review of oral biopsies, sample types, and detection techniques applied in relation to oral cancer detection. *BioTech*. 2022 Mar 2;11(1):5.
16. Bain BJ. Morbidity associated with bone marrow aspiration and trephine biopsy-a review of UK data for 2004. *Haematologica*. 2006 Jan 1;91(9):1293-4.
17. Margarone JE, Natiella JR, Vaughan CD. Artifacts in oral biopsy specimens. *Journal of oral and maxillofacial surgery*. 1985 Mar 1;43(3):163-72.
18. Lolli R, Venezia A, Bellardini M, De Nisi S, Demuro G. Technical artifacts in biopsy of the oral cavity. I. Clinical and histopathologic aspects. *Minerva Stomatologica*. 1989 Jan 1;38(1):37-45.
19. Daley TD, Lovas JL, Wysocki GP. Oral biopsy technique. The pathologist's perspective. *Journal (Canadian Dental Association)*. 1986 Jul 1;52(7):591-5.
20. Conroy JD. Procurement, fixation, and submission of tissue specimens for microscopic examination. *Journal of the American Veterinary Medical Association*. 1971 Jan 1;158(1):99-101.
21. Abbey LM, Sweeney WT. Fixation artifacts in oral biopsy specimens. *Virginia Dental Journal*. 1972 Dec 1;49(6):31-4.
22. Dupuis R. Biopsies: general principles, indications and technics. *Le Journal dentaire du Quebec*. 1985 Mar;22:119-25.